

Increased Intima Media Thickness of Common Carotid Artery in Hypertensive and Pre-Hypertensive Patients – A Systematic Review

Abdul Wahab Afridi¹, Mubarra Chaudhry², Sybil Rose³, Rana Muhammad Athar Azeem Shams⁴, Ambreen Sadaf⁵

ARTICLE INFORMATION

Corresponding Author:

1. wahabafri61@gmail.com

Affiliations:

¹DMIT, MMP, University of Dundee, Nethergate, Dundee DD1 4HN, United Kingdom

²DMIT, The University of Lahore, Lahore Campus, 1-KM Defence Road, Lahore, Pakistan

³MID, MSDU, The University of Lahore, Lahore Campus, 1-KM Defence Road, Lahore, Pakistan

⁴MID, MSMIT, The University of Lahore, Lahore Campus, 1-KM Defence Road, Lahore, Pakistan

⁵BSOT, MSCP, The University of Lahore, Lahore Campus, 1-KM Defence Road, Lahore, Pakistan

Citation:

Received: 21-February-2022

Revised and Accepted: 12-March-2022

Published On-Line: 24-March-2022

ABSTRACT

Background: Adult hypercholesteremic have thicker intima media of the common carotid arteries than controls. Atherosclerotic hypertension (HTN) is a substantial risk factor for cardiovascular and cerebrovascular diseases. HTN causes a fourfold rise in the risk of stroke, and this risk is significantly greater when associated with other risk factors that cause fatal conditions.

Objective: To determine the increased thickness of inner lumen of common carotid artery in hypertensive and pre-hypertensive patients.

Method & Material: From 2003 to 2019, the following keywords were searched in PubMed, ProQuest, Google Scholar, and Research Gate: pre-hypertension, hypertension, IMT, and carotid arteries. The review only included studies that measured intima-media thickness. independently evaluated titles and abstracts of full-length related publications for inclusion and exclusion. The general consensus was fixed by the reviewer's differences. The included studies on the role of ultrasonography in thickened IMT diagnosis. Applicability and quality of studies were assessed using full-length journal data. After scanning databases, 73 papers were found; 14 were duplicates, 34 were irrelevant or lacking data, and 7 were eliminated based on title and abstract, a total of 18 studies were reviewed. This study excluded systematic reviews and meta-analyses in favor of original research publications. This review studies are all prospective.

Result: Intima media thickness increases with hypertension in 18 studies. Age increased the intimal medial thickness ($r=0.6$, $P=.000$). Patients with atherothrombotic changes had higher IMT than those without it. Each patient's sensitivity and specificity were averaged out. With or without plaque, ultrasonography had 87.5 sensitivity. Diverse study designs and analysis precluded pooled calculations.

Conclusion: IMT increases with ageing. IMT also increases in people with other atherosclerosis symptoms including plaque development. IMT thickening occurs in even normotensive person. However, hypertension has no effect on IMT. Hypertension accelerates the severity of IMT and atherosclerosis.

Keywords: Carotid IMT, Hypertensive, Ultrasound, Atherosclerosis, Hypercholesterolemia, Plaque Formation



JBAHS Work Licensed Under 4.0, Based on a work at <http://jbahs.pk>.

Creative Commons Licence Online Research Publications by authors is licensed under a Creative Commons Attribution-Non-commercial, No Derivatives 4.0 International License.

Original Research Article

Introduction:

Adult hypercholesteremic have thicker carotid intima media than non-hypercholesteremic controls ⁽¹⁾. HTN increases the risk of stroke by fourfold when combined with other fatal risk factors ^(2,3). Early preclinical heart and cerebrovascular bed target organ damage can be reliably detected noninvasively ⁽⁴⁻⁸⁾. Chronic HTN expands the carotid artery wall. This hypertrophy causes thickening of the carotid intima media layers, which can be evaluated and examined noninvasively using real-time Doppler ultrasonography ^(6,7). Intima-MT levels are greater in hypertensive patients than in healthy controls ^(9,10). More research has been done on the link between IMT and most atherosclerotic risk factors, and IMT in the elderly has been linked to an increased risk of myocardial localized

necrosis and stroke ⁽⁹⁾. HTN is a major medical issue all over the world because of its high incidence and increased risk of cardiovascular infection. Advances in HTN detection and therapy have significantly reduced coronary artery disease and stroke mortality in developed countries. However, in many of these areas, HTN control rates have declined in recent years. Globally, 1.4 billion people will have hypertension by 2011 ⁽¹¹⁾. The prevalence of hypertension in the US population has been risen. According to the American Heart Association's 2018 coronary disease and stroke insights update, over 34% of Americans have hypertension (140/90 mm Hg analytic SBP/DBP). The AHA and ACoC 2017 circulatory strain standards lowered the threshold for hypertension to 130/80 mm Hg, resulting in an additional 45% of US adults having

hypertension ⁽¹²⁾. A new BP categorization called “pre HTN” was recommended by the Joint National Committee on Prevention, Detection, Evaluation, and Treatment of Hypertension in 2004. The reclassification was made to emphasize the high risk of BP in this range and to increase clinical and general health concerns ⁽¹³⁾. Extracranial carotid ultrasonography is now frequently used to detect early blood vessel divider abnormalities. Also, IMT of the carotid divider has been associated with early atherosclerosis and coronary conduit atherosclerosis ⁽¹⁴⁾ exercises is related with IMT of normal carotid. A freely old enough and built-up atherosclerotic hazard factors. Carotid Intima media thickness in hypercholesterolemia patients was expanded and carotid bifurcation is principal location for Plaque formation.

Material and Methods

Search Strategy:

The databases PubMed, ProQuest, Google Scholar and Research Gate were searched from 2003 to 2019 for pre-hypertension, hypertension, intima media thickness and carotid arteries. The evaluation only included the studies that measured Intima Media Thickness.

Selection Criteria:

Independently evaluated titles and abstracts of full-length linked publications are selected for inclusion and deletion. Consensus fixed the reviewer's differences. The included studies are on the role of ultrasonography in thickened IMT diagnosis. Applicability and quality of studies were assessed using full-length journal data.

Study Characteristics:

After scanning databases, 73 papers were found, 14 were duplicates, 34 were irrelevant or lacking data, and 7 were eliminated based on title and abstract. A total of 18 studies were reviewed. Figure 1: Flow chart summarizing reviewed records. This study excluded systematic reviews and meta-analyses in favour of original research publications. This review's studies are all prospective.

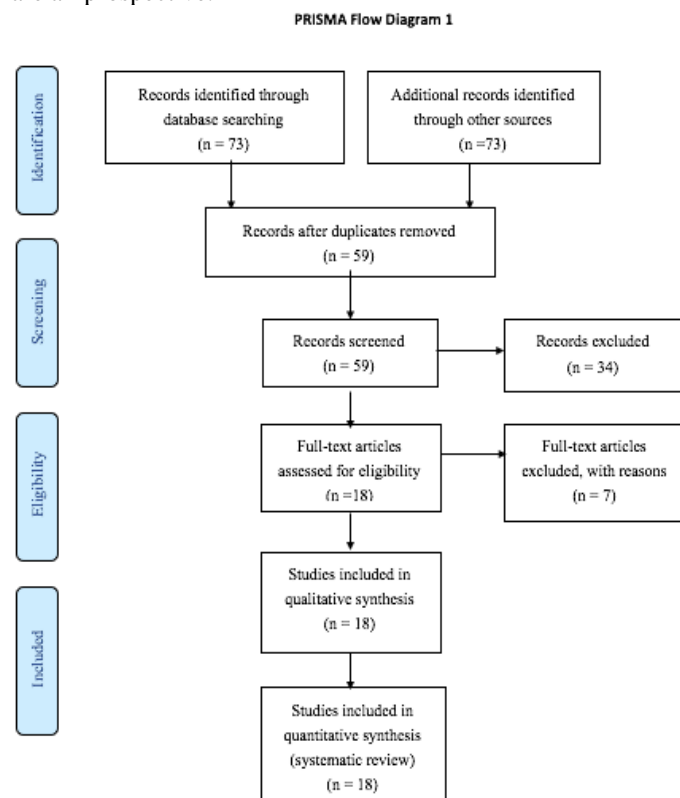


Figure 1: Flow chart summarizing reviewed records

Results

Intima medium thickness is increased with hypertension in 18 studies. Age increased the intimal medial thickness ($r = 0.6$, $P = .000$). Patients with atherothrombotic changes had higher IMT than those without. Each patient's sensitivity and specificity were averaged out. With or without plaque, ultrasonography had 87.5 sensitivity. Diverse study designs and analysis precluded pooled calculations.

Discussion

IMT is associated to atherosclerosis, B-Mode Ultrasonography, a high-resolution imaging method, may quantify the CCA's intimal medial thickness. Children with primary hypertension had thicker carotid intima media, according to Lande et al. Carotid intima medium thickness was assessed in hypertensive and non-hypertensive children. Children with newly diagnosed office hypertension ($n = 28$) were measured. This study matched 28 hypertensive adults by age (1 year), gender, and BMI (10 percent). 82 % of individuals were obese (85th percentile body mass index). It was shown that HTN had 0.67 mm more intima media than HTN controls (0.63 mm; $P = 0.045$). Carotid intima media thickness was linked with daytime systolic blood pressure index in hypertensive patients ($r = 0.57$; $P = 0.003$). Left ventricular mass index did not connect with ambulatory blood pressure monitoring. There is substantial evidence that carotid intima media thickness is increased in children primary hypertension, regardless of obesity effects ⁽¹⁵⁾. White coat hypertension was evaluated clinically by Efstathios Manios et al. in 2016. (WCH). We compared CCAIMT values for isolated systolic, isolated diastolic, and systolic/diastolic WCH to other BP phenotypes. ambulatory blood pressure monitoring and carotid ultrasonography. WCH was classified as systolic, diastolic, and systolic/diastolic. Their difference ($n = 228$) from systolic/diastolic WCH ($n = 112$) was not statistically significant (0.708 mm). These findings suggest that patients with WCH have a higher risk of CCAIMT than those with WCH that is isolated systolic/diastolic ⁽¹⁶⁾. Shams R. M. A. A. et al. examined carotid intima media thickness in normotensive and hypertensive patients in 2020. Among 70 persons tests, 40 were hypertensive and 30 were normal. The anterior wall intima-media thickness of CCA distal segment was measured in hypertensive and normal Pakistanis. An MRI scan revealed 40 persons with hypertension (57%) and 30 without hypertension or any neurological condition (42%) in this case-control study. Age and intimal medial thickness ($r = 0.6$, $P = 0.000$). Plaques patients exhibited higher IMT than non-plaques patients. Hypertensive and normotensive patients use ultrasonography with 50.0 and 66.7 sensitivity. Both with and without plaque, ultrasound had 87.5 sensitivity and 87.1 specificity. Age raises IMT. Like other atherosclerotic symptoms, IMT rises ⁽¹⁷⁾. They investigated whether atherosclerotic carotid IMT is associated to changes in carotid baroreceptor sensitivity. This study intended to relate carotid IMT to autonomic HRV control (HRV). This study involved 101 people. Duplex ultrasonography determined the carotid IMT. The Deep Breathing Test measures HRV, their models included demographics, comorbidities and BMI/WHR as well as left ventricular ejection fraction. Participants had a 10-year ASCVD risk score of 16.4 out of 17. SDNN first quartile (0.90.19) then 0.820.12 (36.55.7) 0.810.16 (57.76.2) and 0.680.19 (Q4). (OR 0.002, 95 percent CI 0.003–0.001, $P = 0.005$). The carotid IMT correlated well with other HRV data including CV and point dispersion along the line of identity

(SD2). Changes in HRV were associated to changes in carotid IMT, a marker of subclinical atherosclerosis ⁽¹⁸⁾.

Conclusion

IMT get increased with ageing. IMT also increases in persons with other atherosclerosis symptoms including plaque development. IMT thickening occurs in even normotensive persons. However, hypertension has no effect on IMT. Hypertension accelerates the severity of IMT and atherosclerosis.

References:

1. Pauciullo P, Iannuzzi A, Sartorio R, Irace C, Covetti G, Di Costanzo A, Rubba P. Increased intima-media thickness of the common carotid artery in hypercholesterolemic children. *Arteriosclerosis and thrombosis: a journal of vascular biology*. 1994 Jul;14(7):1075-9.
2. Levy D, Bairey Merz CN, Cody RJ, Fouad-Tarazi FM, Francis CK, Pfeffer MA, Scott NA, Swan HJ, Taylor MP, Weinberger MH. Hypertension detection, treatment and control: a call to action for cardiovascular specialists. *Journal of the American College of Cardiology*. 1999 Oct;34(4):1360-2.
3. Waldstein SR, Manuck SB, Ryan CM, Muldoon MFJpb. Neuropsychological correlates of hypertension: review and methodologic considerations. 1991;110(3):451.
4. Vaudo G, Schillaci G, Evangelista F, Pasqualini L, Verdecchia P, Mannarino EJAJoh. Arterial wall thickening at different sites and its association with left ventricular hypertrophy in newly diagnosed essential hypertension. 2000;13(4):324-31.
5. Casiglia E, Palatini P, Da Ros S, Pagliara V, Puato M, Dorigatti F, et al. Effect of blood pressure and physical activity on carotid artery intima-media thickness in stage 1 hypertensives and controls. 2000;13(12):1256-62.
6. Howard G, Sharrett AR, Heiss G, Evans GW, Chambless LE, Riley WA, et al. Carotid artery intimal-medial thickness distribution in general populations as evaluated by B-mode ultrasound. ARIC Investigators. 1993;24(9):1297-304.
7. Burke GL, Evans GW, Riley WA, Sharrett AR, Howard G, Barnes RW, et al. Arterial wall thickness is associated with prevalent cardiovascular disease in middle-aged adults: the Atherosclerosis Risk in Communities (ARIC) Study. 1995;26(3):386-91.
8. Ficzer A, Valikovics A, Fülesdi B, Juhász A, Czuriga I, Csiba LJJocu. Cerebrovascular reactivity in hypertensive patients: a transcranial Doppler study. 1997;25(7):383-9.
9. Lemne C, Jogestrand T, de Faire UJS. Carotid intima-media thickness and plaque in borderline hypertension. 1995;26(1):34-9.
10. Pauletto P, Palatini P, Da Ros S, Pagliara V, Santipolo N, Baccillieri S, et al. Factors underlying the increase in carotid intima-media thickness in borderline hypertensives. 1999;19(5):1231-7.
11. Fagan TCJAoim. Evolution of the Joint National Committee Reports, 1988-1997: Evolution of the Science of Treating Hypertension. 1997;157(21):2401-2.
12. Kaplan NM. Kaplan's clinical hypertension: Lippincott Williams & Wilkins; 2010.
13. Svetkey LPJH. Management of prehypertension. 2005;45(6):1056-61.
14. Ghiadoni L, Taddei S, Virdis A, Sudano I, Di Legge V, Meola M, et al. Endothelial function and common carotid artery wall thickening in patients with essential hypertension. 1998;32(1):25-32.
15. Lande MB, Batisky DL, Kupferman JC, Samuels J, Hooper SR, Falkner B, Waldstein SR, Szilagyi PG, Wang H, Staskiewicz J, Adams HR. Neurocognitive function in children with primary hypertension. *The Journal of pediatrics*. 2017 Jan 1;180:148-55.
16. Manios E, Michas F, Stamateopoulos K, Koroboki E, Lykka A, Vettou C, Vemmos K, Zakopoulos N. White-coat isolated systolic hypertension is a risk factor for carotid atherosclerosis. *The Journal of Clinical Hypertension*. 2016 Nov;18(11):1095-102.
17. Shams RM, Naeem A, Yousaf M, Hanjra HH, ul Abidin SZ. Sonographic Assessment of Intima Media Thickness of Common Carotid Artery in Normotensive and Hypertensive Individuals. *Asian Journal of Allied Health Sciences (AJAHS)*. 2020 Aug 28:38-42.
18. Pereira Jr VL, Dobre M, Dos Santos SG, Fuzatti JS, Oliveira CR, Campos LA, Brateanu A, Baltatu OC. Association between carotid intima media thickness and heart rate variability in adults at increased cardiovascular risk. *Frontiers in Physiology*. 2017 Apr 26;8:248.